


Automatic Curvature Analysis for Finely Interpolated Spinal Curves

Conference Paper**Author(s):**

Neghină, Mihai; Petruse, Radu E.; [Cukovic, Sasa](#) ; Schiau, Călin; Filipović, Nenad

Publication date:

2021

Permanent link:

<https://doi.org/10.3929/ethz-b-000525449>

Rights / license:

[In Copyright - Non-Commercial Use Permitted](#)

Originally published in:

<https://doi.org/10.1109/BIBE52308.2021.9635424>

Funding acknowledgement:

892729 - From Skin to Skeleton: Revolutionary Contactless and Non-Ionizing 3D Digital Diagnosis and (EC)

Automatic Curvature Analysis for Finely Interpolated Spinal Curves

Mihai Neghină
Computer Science and Electrical
Engineering.
Lucian Blaga University of Sibiu
Sibiu, Romania
mihai.neghina@ulbsibiu.ro

Radu Emanuil Petrusc
Industrial Engineering and
Management
Lucian Blaga University of Sibiu
Sibiu, Romania
radu.petrusc@ulbsibiu.ro

Saša Čuković
Institute for Biomechanics
Swiss Federal Institute of Technology
ETH Zurich
Zurich, Switzerland
sasa.cukovic@hest.ethz.ch

Călin Schiau
Department of Radiology
University of Medicine and Pharmacy
"Iuliu Hatieganu"
Cluj-Napoca, Romania
calin.schiau@yahoo.com

Nenad Filipović
Faculty of Engineering
University of Kragujevac
Kragujevac, Serbia
fica@kg.ac.rs

Abstract — Assessment of the spinal disorders is a notoriously difficult problem, even in controlled environments where the patients are instructed to stand upright. The method presented here considers the analysis of the mathematical curvature of the scaled and interpolated spinal line, in both the sagittal and frontal planes. Although the number of assumptions for spine normality is kept to a (reasonable) minimum, we demonstrate good detection of sharp or otherwise unnatural local bending in adolescent spinal alignments.

Keywords—Spinal alignment, Curvature analysis, Vertebral centroids, Scoliosis

I. INTRODUCTION

Spinal analysis has evolved greatly in the last 100 years since the introduction of quantitative evaluations by Fergusson [1]. The importance of spinal vertical alignment in relation to the internal coordinate system has been recognized since the earliest studies, after which the methods have been mostly result-oriented, with the explicit purpose of labelling the severity of scoliosis, kyphosis or lordosis on the spine as a whole. Scoliosis is almost exclusively analysed using Cobb method [2], adopted by the Scoliosis Research Society (SRS) as the gold standard for quantification of scoliotic deformities and reflecting changes in vertebrae inclination. Although many attempts have been made to amend the method or improve the reliability of the measurements through computer assistance, including the following from three different decades [3][4][5], the basic principle of angle measurement has remained unchanged.

The evaluation of sagittal projection, on the other hand, has been tried with a variety of methods, including Modified Cobb [6][7], the Ishihara index [8], circle [9] and ellipse fitting [10], as well as analysis of mathematical models (polynomial approximations [11], spline interpolation [12]). Yang et al. [12] describes a manual selection of posterosuperior aspects of each vertebral body as representative points on the spine projection in the sagittal plane (rotated so that the rostral direction corresponds to the x-axis), followed by the spline interpolation on these points and the computation of areas on the interpolated curve. Singer et al. [14] computes the mean radius of curvature over large regions of the spine, also restricted to the sagittal plane, roughly the regions where Cobb angles could be computed.

Falling into the category of mathematical models, the proposed method highlights a mathematical tool for uniform analysis in both projections. After the centroids of vertebrae

and intervertebral discs are computed automatically as described in Čuković et al. [13], cubic spline interpolation similar to Yang et al. [12] is considered, assuring that the resulting curve is smooth, twice differentiable and passing through all the points. One difference to the aforementioned method of Yang et al. is that the points on the spine are computed automatically in three dimensions. Another difference is that both vertebrae and intervertebral discs are points of interest. More importantly still, instead of the area under the curve (integral analysis), the proposed method considers the mathematical curvature computation, which is more in line with Singer et al. [14] mean radius, but in a much finer detail, revealing local curvature changes. In focusing on the curvature rather than the diagnosis, the method is aimed at identifying problematic regions on the spine that may be the principal cause for spinal deformities.

The paper is structured as follows: Section 2 describes the proposed method; Section 3 provides details on the database used in experiments; Section 4 describes the experiments and results; Section 5 offers the conclusions and perspectives regarding the utility and further development of the method.

II. THE PROPOSED METHOD

The proposed method can be summarized as in Fig. 1 and includes the acquisition of data, which can be done using optical or X-ray devices, pre-processing for spine orientation and scaling, interpolation, the computation of the frontal and sagittal projections and the computation of curvature on each of the projections. The first step after the acquisition of data, is the computation of centroids for all vertebrae and vertebral discs as three-dimensional vectors. These vectors are transformed to an internal set of coordinates based on the axis L5-C7, with the purpose of setting up the spine vertically. Scaling of the spine to a 500 mm axis is also performed at the pre-processing stage, enabling a uniform set of vertical coordinates for all spines of the set. The cubic spline interpolation is then considered on points of data, to provide a continuous and twice differentiable curve to work with. The curve and its first and second order derivative are used to compute the mathematical curvature and compare it to (loose) limits inferred from the natural language description of a normal spine. Spines exhibiting excessive local bendings are marked with an intuitive colour code, green to yellow in the frontal plane and green to magenta in the sagittal plane. While not intended to offer a diagnosis, the colouring emphasizes the problem regions of the analysed spines. Each of the steps are described in more detail in sub-sections A through E.

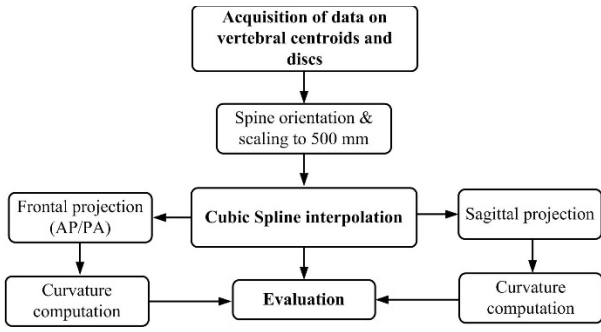


Fig. 1. Proposed method flowchart

A. Data Acquisition

For the suggested method, the tools for acquiring the coordinates of vertebrae and intervertebral centroids, be they CT scans, EOS imaging or 3D optical scanning, are not important. However, the analysis (obviously) benefits from more accurate data. For estimating centroid positions ScolioSIM tool based on non-invasive optical diagnosis is used. Coordinates of every centroid were calculated from local spinal axes that connects C7 and S1-L5 vertebrae in 3D [15-17].

For this stage, the assumption is that the patient is instructed to stand upright, arms alongside the body. In Fig. 2, the X coordinate is the approximate front-back displacement in the sagittal plane, the Y coordinate is the vertical component, and the Z coordinate is the approximate lateral displacement in the frontal plane.

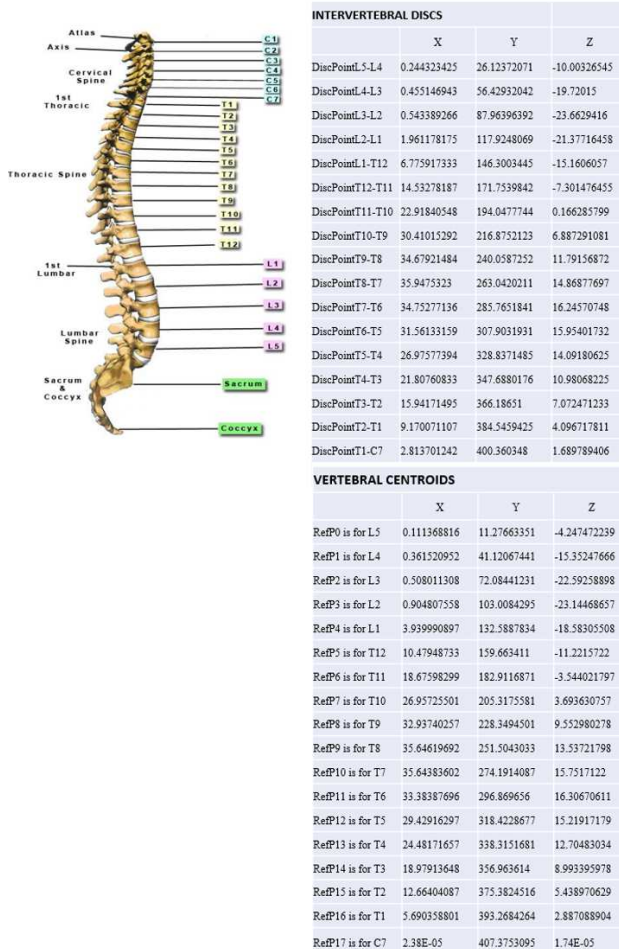


Fig. 2. Coordinates for discs and vertebral centroids

B. Data Pre-Processing

The pre-processing stage refers to the linear transformations performed on the raw data, namely the adjustment in the coordinates and the uniform scaling, necessary to represent the data as a 500 mm C7-L5 spine in the local system of coordinates, vertebrae C7 and L5 having coordinates [0,500,0] and [0,0,0] respectively.

The perfect vertical alignment of the L5-C7 line is properly accomplished by a rotation. However, if the data acquisition is good enough that both vertebrae L5 and C7 are very close to the vertical axis (e.g., around 10 mm away from it), the rotation can be replaced by the less computationally intensive shearing, or even skipped entirely. If so, the only absolutely necessary operations at this stage are the vertical translation (needed to place L5 at height 0 mm) and the uniform 3D scaling (needed to place C7 at height 500 mm without distorting the geometric ratios).

C. Cubic Spline Interpolation

Considering that the further steps involve the analysis of the mathematical curvature, which requires the computation of up to the second derivative, the plain cubic spline interpolation with the not-a-knot constraint has been considered. The interpolated curve is theoretically continuous and has continuous first and second order derivatives. Practically, the interpolation done by a computer is discrete, but the interpolation step can be as small as required. For this experiment, an interpolation step of 0.1 mm was chosen.

D. Computation of Curvature

For a one-dimensional curve in two-dimensional space y , the extrinsic curvature k at a particular point, computed with eq. (1), can be interpreted as the reciprocal of the radius of a circle tangent to the curve at the considered point, that best approximates the curve around that point.

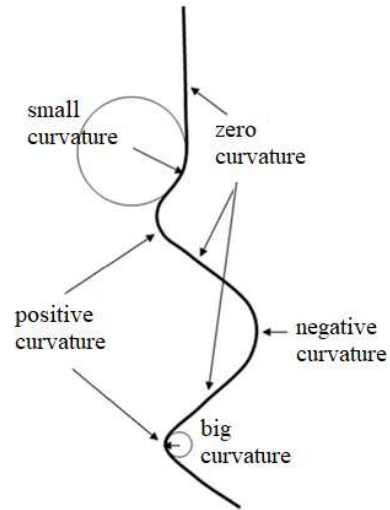


Fig. 3. Graphical explanation of curvature

Straight lines have a curvature $k = 0$, regardless of orientation. The tighter the curve turns, the larger the curvature is. The sign of the curvature is an indication of the concavity/convexity of the curve with respect to the ordinate axis (which in this context will be the vertical or height axis of the spine).

$$k = \frac{y''}{(1 + y'^2)^{3/2}} \quad (1)$$

With this in mind, the curvature can be computed separately on the frontal and the sagittal projections. In mathematics, there are equations for the curvature of a one-dimensional curve in N-dimensional space and it is possible to compute the 3D curvature of the spine, but it would be considerably more difficult to define assumptions (and thus to assess the problems in the spine) than considering the projections in the frontal and the sagittal planes.

E. Assumptions on Spine Curvature

The assumptions considered at this stage follow the natural language description of a normal spine, represented in Fig. 4. Since the spines have been normalized and orientated, the vertical axis in Fig. 4 and all subsequent figures will always read the height above L5, with C7 always being at 500 mm. This will be indicated in the figures as the ‘Spine [mm]’ label. The horizontal axis can be the side-to-side displacement (for the frontal view), the front-to-back displacement (for the sagittal view) or the curvature (for both views).

ASSUMPTION 1: *The frontal projection of the spine should be straight (i.e. have 0 curvature).* For evaluating how extreme a frontal curvature is, we have considered two-sided oscillations on the full 500 mm length of the spine and various apex points. For example, a curvature of $\pm 2 \cdot 10^{-3} \text{ mm}^{-1}$ would amount to an apex of 15.9 mm on each side and a subtending angle of 29 deg., as shown in Table I and Fig. 5.

The frontal curvature is computed as a real number, with no natural distinction between classes such as “low” or “extreme” bending. For the sake of exemplification, Fig. 6 shows, for a real spine example, the displacement of vertebrae and discs (left) and the computed curvature (right), including green marking for what could be considered a small curvature and yellow markings for what could be considered a large curvature.

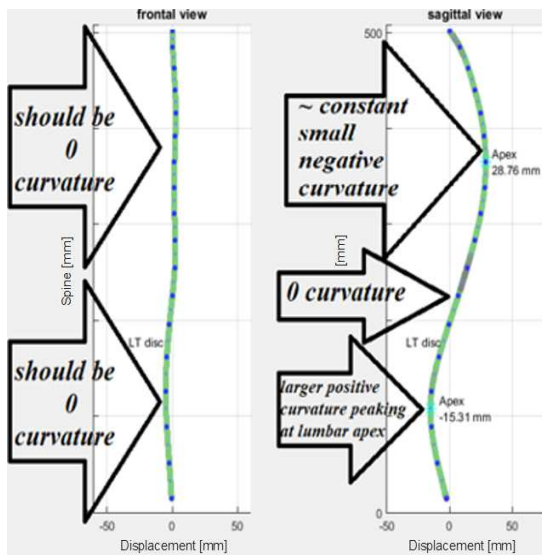


Fig. 4. Natural language description of a normal spine

TABLE I. FRONTAL CURVATURE DESCRIPTION

Curvature k [$\times 10^{-3} \text{ mm}^{-1}$]	Apex [mm]	Subtending angle [deg.]
1	7.8	14
2	15.9	29
3	24.3	44
4	33.5	60
5	43.8	77

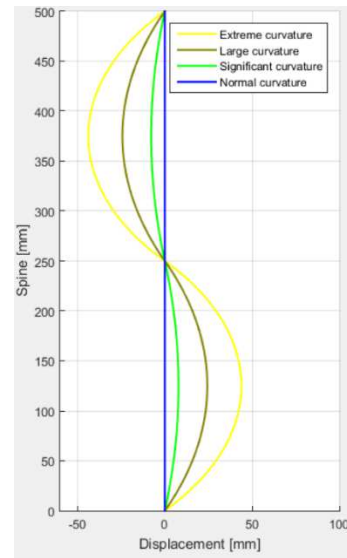


Fig. 5. Frontal curvature evaluation using two-sided oscillations on the full length of the spine

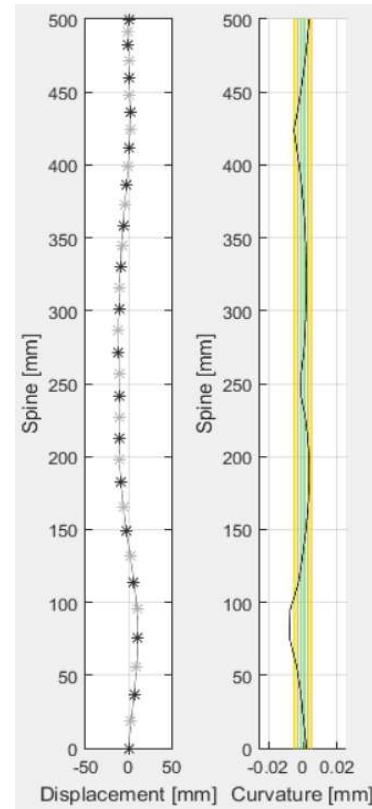


Fig. 6. Frontal view displacement (left) and curvature (right)

ASSUMPTION 2: *In the sagittal projection from the left side of the subject, the thoracic curvature should be negative, small and relatively constant; the lumbar curvature should be positive, slightly larger and peaking at the lumbar apex.* Acceptable values of curvature in the sagittal plane have been determined by considering arcs of a circle, which have constant curvature intrinsically. The thoracic arcs, considered to span the upper 300 mm of the spine, would exhibit curvatures and apices as shown in Table II and Fig. 7. The negative sign of the normal thoracic curvature, as viewed from the left side projection of the subject, has been left out of the table. The arcs subtending a 100 mm chord around the lumbar apex are also shown in Fig. 7.

The lateral curvature is also computed as a real number, with no natural distinction between classes such as “low” or “extreme” bending. Compared to the frontal projection, the sagittal projection must evaluate how extreme a curvature is compared to what could be considered normal curvature of the spine. Taking the blue curve segments from Fig. 7 as normal and connecting the missing parts by linear interpolation, an estimate on the expected curvature values can be computed at all heights. Similar to Fig. 6 for the frontal projection, Fig. 8 for the sagittal projection shows the displacement and the curvature, with coloured lines indicating the severity of the curvature. One important observation is that these coloured lines are computed dynamically, based on the lumbar apex, and may differ from one spine to another.

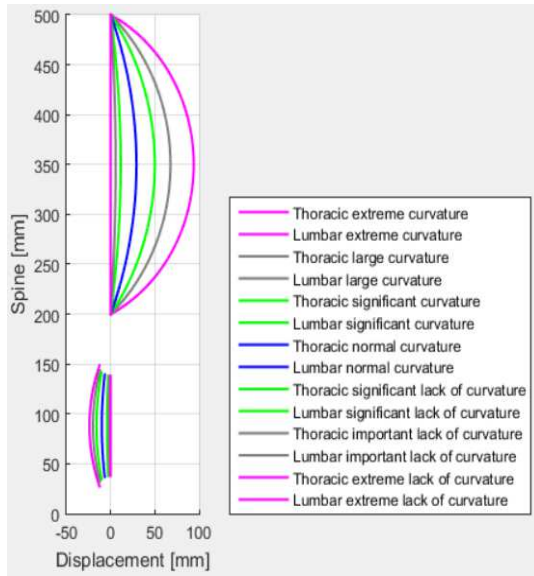


Fig. 7. Sagittal curvature evaluation using arcs of circles

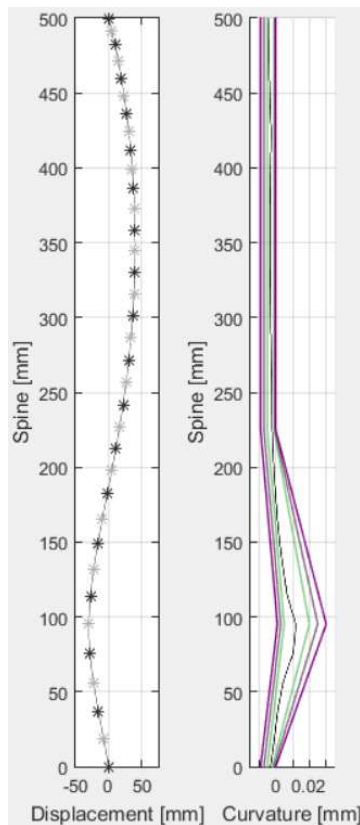


Fig. 8. Sagittal view displacement (left) and curvature (right)

TABLE II. LATERAL THORACIC CURVATURE DESCRIPTION

Curvature k [$\times 10^{-3} \text{ mm}^{-1}$]	Apex [mm]	Subtending angle [deg.]
0	0	N.A.
0.5	5.6	9
1	11.3	17
2.5	29.1	45
4	50.0	73
5	67.7	97
6	94.0	128

III. DATABASE AND REFERENCE EVALUATIONS

The database is composed from 23 sets of spinal coordinates taken from adolescent idiopathic patients standing in the upright position, with relaxed arms close to the body. For each set of coordinates, the normalized 500 mm interpolated projections have been given to a clinical medical doctor (M.D.) for evaluation of the severity of the bending. These evaluations, which will be used as reference in the experiments, are returned as tables indicating, for each table line, the abnormal region (from height h_1 [mm] to height h_2 [mm]) and the general severity in the region. Regions not covered by the tables are supposed to have normal curvature. Table III gives an example of evaluation from the M.D.

Because each spine can have multiple problematic regions for each projection, the number of samples considered in the experiment is therefore 42 frontal regions and 51 lateral regions, totalling 93 regions. The size of the indicated regions can be as low as 30 mm and as large as 250 mm, but it is usually around 100 mm., as shown in the Fig. 9 histogram.

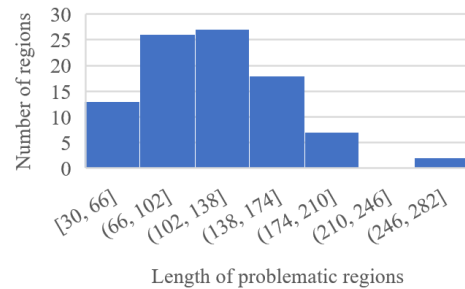


Fig. 9. Length of problematic regions histogram

In physiologically normal spine, frontal projection of the internal spinal alignment is straight line, while sagittal profile has natural “S” shape. In the case of scoliosis each projection can contain couple of curvature segments depending on the severity. To support classification, known ranges of angles in specific regions of the sagittal profile could be considered, or more specifically upper thoracic, mid thoracic, thoracolumbar and lumbar angles.

TABLE III. MEDICAL DOCTOR EVALUATION EXAMPLE

Spine 01				
(FRONTAL)				
From [mm]	To [mm]	Slightly Abnormal Curvature	Moderately Abnormal Curvature	Extremely Abnormal Curvature
330	400			√
170	190	√		
0	150	√		
(LATERAL)				
270	420		√	
60	130		√	

IV. RESULTS AND INTERPRETATION

As indicated in the theoretical sections, the computer evaluation generates curvature values as real numbers (without restrictions) and on the entire length of the spine. While the results can be analysed in many ways, one of the most straightforward and intuitive comparisons is checking the maximal abnormal curvature for each indicated interval.

For the frontal projection, the absolute maximum value in the indicated interval is considered (in order to account for both convex and concave curvature), but the sign is preserved in the Fig. 10 representation. Also, the position along the spine of the maximum is preserved. Such points are represented as round markers if the M.D. indicated a slightly abnormal curvature on the interval, square markers if the M.D. considered the interval to be moderately abnormally curved and triangle markers if the M.D. saw an extremely abnormal curvature. The background colours correspond to the line colours in Fig. 5 and Fig. 6, with the greenest patch around the Y-axis indicating no curvature (the normal state of the frontal projection of the spine) and becoming more and more yellow as the curvature becomes more and more severe.

As it can be seen in Fig. 10, almost all segments deemed extremely abnormal bendings (triangles) fall firmly in the yellow patch, the moderately abnormal bendings (squares) are close to the edge of the yellow region, generally closer to the Y-axis than triangles, while the slightly abnormal bendings fall mostly at the outer edge of the green patch.

This result shows a very good correlation between the expert evaluation and the computed curvature values and the background colours and thresholds between various classes can be easily adjusted to fit that evaluation in most cases.

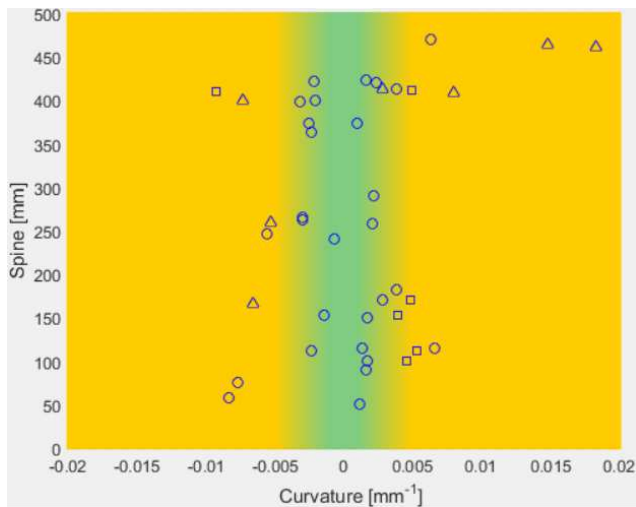


Fig. 10. Frontal curvature evaluation results

For the sagittal projection, the curvature values are against expected values that are generated dynamically taking into consideration the lumbar apex. This dynamic map is problematic to represent in the same way as the background of the frontal projection, so a static-coloured background has been chosen in Fig. 11 for all data points, in order to convey the general feeling where the points would fall on such a map.

While there are relatively few triangles, the squares are all clustered around the edge of the green area and the round markers are usually just over the edge.

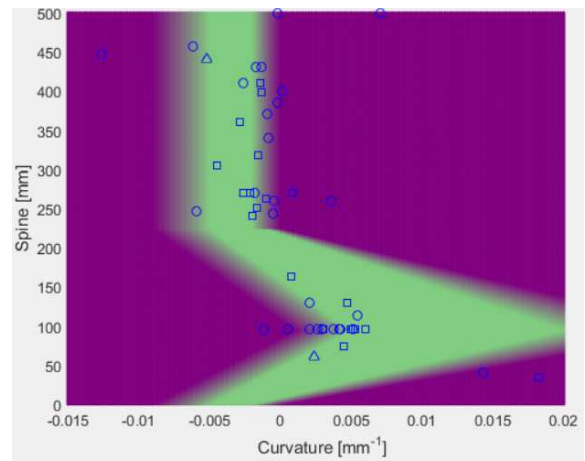


Fig. 11. Sagittal curvature evaluation results

Although the method is not constructed for the diagnosis of scoliosis, kyphosis or lordosis, the clinical application is the identification and representation of problem regions in a graphical and intuitive way. Fig. 12 shows an example of the spine evaluation in both planes. For the frontal plane, the more extreme the curvature is, the yellower and larger the corresponding region of the spine becomes in the representation. For the sagittal plane, the more abnormal the curvature is, the more magenta and larger the corresponding region of the spine becomes in the representation. The colours scheme corresponds to Fig. 10 and Fig. 11.

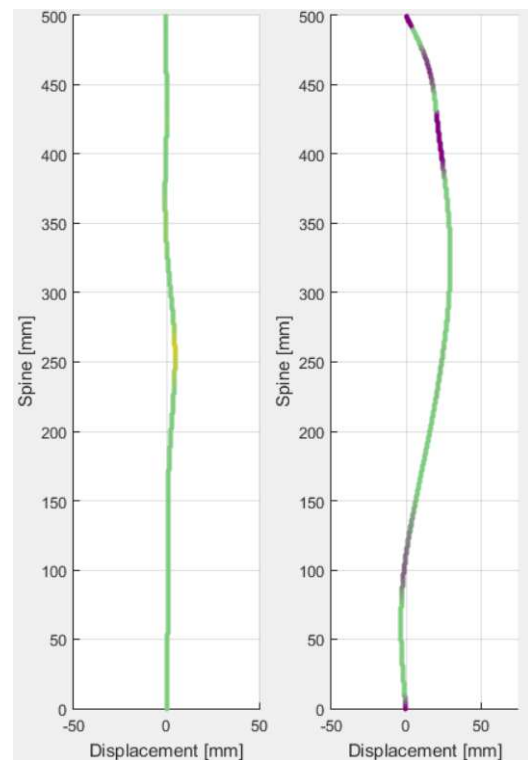


Fig. 12. Automatic evaluation of problematic regions in the frontal (left) and sagittal (right) plane

In the Fig. 12 example, the frontal projection looks rather straight, with only a small region of relatively larger curvature around the height of 250 mm. In the sagittal plane, there are multiple abnormal curvature, including a straight region around 400 mm and a quite quick return to the axis around the 100 mm mark, not allowing the full lumbar shape to occur.

The Fig. 12 representation could help doctors quickly identify problematic regions to focus their investigations or can be an initial step towards fully automated diagnosis.

V. CONCLUSIONS AND PERSPECTIVES

The proposed method of analysis of the spine has been generated from simple, common speech descriptions of the normal spine. The numerical limits of the curvature that a normal spine could exhibit have been derived from these and tested against M.D. evaluations. While there has been a good correlation between M.D. evaluation and computer-generated evaluations in the frontal projection, the comparison is a little less clear in the sagittal projection. One perspective would be to analyse closer the outliers, especially the samples that are evaluated very differently by the M.D. and the program, to understand where the discrepancy lies.

Also, the method is not perfect in another sense as well. The conditions derived from assumptions, while necessary, may not be sufficient by themselves to ensure a normal spine or to suggest the complete lack of afflictions, such as scoliosis or kyphosis, but offer information on the location of sharp and unnatural turns of the spine. In general, scoliosis would produce sharp turns in the frontal projection and kyphosis/lordosis would produce unnatural turns in the sagittal plane. But a slow drift in either projection could, conceivably and misleadingly, fall within the conditions, while still generating a mild affliction. For a more thorough automatic investigation, the statistical properties of the projections would also need to be taken into account.

Nevertheless, the method presented can produce intuitive graphical representations of the problematic regions to help doctors with the initial assessment of the spine. It can also be the starting point for automatically computing traditional measures, such as Cobb angles for fully automated diagnoses.

ACKNOWLEDGMENT

Proposed study was partially financed by the Serbian Ministry of Education, Science and Technological Development (Agreement No. 451-03-9/2021-14/200378), by the European Union's Horizon 2020 research and innovation programme under the Marie Skłodowska - Curie (MSC grant agreement No. 892729) and project that has received funding from the European Union's Horizon 2020 research and innovation programme under grant agreement No. 952603 – SGABU (<http://sgabu.eu/>).

REFERENCES

- [1] A. Ferguson, "The study and treatment of scoliosis". *South Med J.* vol. 23, pp. 116–120, 1930
- [2] J. Cobb, "Outline for the study of scoliosis". *Am Acad Orthop Surg Instr Course Lect.* vol. 5, pp. 261–275, 1948
- [3] B. Jeffries, M. Tarlton, A. Smet, S. Dwyer and A. Brower, "Computerized measurement and analysis of scoliosis: a more accurate representation of the shape of the curve", *Radiology.* vol. 134, pp. 381–385, 1980
- [4] K. Shea, P. Stevens, M. Nelson, J. Smith, K. Masters and S. Yandow, "A comparison of manual versus computer-assisted radiographic measurement: Intraobserver measurement variability for Cobb angles". *Spine.* vol. 23, pp. 551–555, 1998
- [5] B. Wills, J. Auerbach, X. Zhu, M. Caird, B. Horn, J. Flynn, D. Drummond, J. Dormans and M. Ecker, "Comparison of Cobb angle measurement of scoliosis radiographs with preselected end vertebrae: traditional versus digital acquisition". *Spine.* vol. 32, pp. 98–105, 2007
- [6] S. Voutsinas, and G. MacEwen, "Sagittal profiles of the spine". *Clin Orthop Relat Res.* vol. 210, pp. 235–242, 1986
- [7] A. Briggs, T. Wrigley, E. Tully, P. Adams, A. Greig and, K. Bennell, "Radiographic measures of thoracic kyphosis in osteoporosis: Cobb and vertebral centroid angles". *Skeletal Radiol.* vol. 36, pp. 761–767, 2007
- [8] A. Ishihara, "A Roentgenographic studies on the normal pattern of the cervical curvature". *Nihon Seikeigeka Gakkai Zasshi,* vol. 42, pp. 1033–1044, 1968
- [9] G. Vaz, P. Roussouly, E. Berthonnaud and J. Dimnet, "Sagittal morphology and equilibrium of pelvis and spine" *Eur Spine J.* vol. 11, pp. 80–87, 2002
- [10] T. Janik, DD. Harrison, R. Cailliet, S. Troyanovich and DE. Harrison, "Can the sagittal lumbar curvature be closely approximated by an ellipse?" *J Orthop Res,* vol. 16, pp. 766–770, 1998
- [11] K. Singer, T. Jones and P. Breidahl, "A comparison of radiographic and computer-assisted measurements of thoracic and thoracolumbar sagittal curvature". *Skeletal Radiol,* vol. 19, pp. 21–26, 1990
- [12] B. Yang, C. Yang, and S. Ondra, "A novel mathematical model of the sagittal spine". *Spine,* vol. 32, pp. 466–470, 2007
- [13] S. Ćuković, G. Devedžić, V. Luković, N. Anwer, T. Luković, and K. Subburaj, "3D modelling of spinal deformities shapes using 5th degree B-splines", *MMA 2015 - Flexible technologies,* Novi Sad, 2015, September 25–26, pp. 223–226, ISBN 978-86-7892-722-5
- [14] K. Singer, S. Edmondston, R. Day, and W. Breidahl, "Computer-assisted curvature assessment and Cobb angle determination of the thoracic kyphosis: an in vivo and in vitro comparison". *Spine,* vol. 19, pp. 1381–1384, 1994
- [15] S. Ćuković, W. R. Taylor, C. Heidt, G. Devedžić, V. Luković, and T. Bassani, "Transpositions of Intervertebral Centroids in Adolescents Suffering from Idiopathic Scoliosis Optically Diagnosed". *International Symposium on Computer Methods in Biomechanics and Biomedical Engineering – CMBBE2019.* pp. 133–141, 2019
- [16] G. Devedžić, S. Ćuković, V. Luković, D. Milošević, K. Subburaj and T. Luković, "ScolioMedIS: Web-oriented information system for idiopathic scoliosis visualization and monitoring," *Comput. Methods Programs Biomed.,* vol. 108, no. 2, pp. 736–749, 2012, doi: 10.1016/j.cmpb.2012.04.008.
- [17] V. Luković, S. Ćuković, D. Milošević, and G. Devedžić, "An ontology-based module of the information system ScolioMedIS for 3D digital diagnosis of adolescent scoliosis," *Comput. Methods Programs Biomed.,* vol. 178, pp. 247–263, 2019, doi: 10.1016/j.cmpb.2019.06.027.