


# Alternative minimally invasive surgical explantation techniques for failed transcatheter mitral valve repair devices

## Journal Article

**Author(s):**

Akansel, Serdar; Kofler, Markus; Van Praet, Karel M.; Sündermann, Simon H.; Unbehaun, Axel; Jacobs, Stephan; Falk, Volkmar  Kempfert, Jörg

**Publication date:**

2023-10

**Permanent link:**

<https://doi.org/10.3929/ethz-b-000641218>

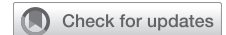**Rights / license:**

[Creative Commons Attribution-NonCommercial-NoDerivatives 4.0 International](#)

**Originally published in:**

JTCVS Techniques 21, <https://doi.org/10.1016/j.xjtc.2023.05.023>

# Alternative minimally invasive surgical explantation techniques for failed transcatheter mitral valve repair devices



Serdar Akansel, MD,<sup>a,b</sup> Markus Kofler, PhD,<sup>a,b,c</sup> Karel M. Van Praet, MD,<sup>a,b,c</sup> Simon H. Sündermann, PhD,<sup>a,b,c</sup> Axel Unbehaun, PhD,<sup>a,b</sup> Stephan Jacobs, PhD,<sup>a,b</sup> Volkmär Falk, PhD,<sup>a,b,c,d</sup> and Jörg Kempfert, PhD<sup>a,b,c</sup>

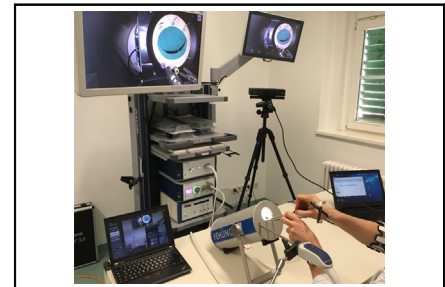
## ABSTRACT

**Objective:** The use of transcatheter mitral valve repair (TMVr) devices is increasing in elderly and high-risk patients. However, the increasing number of patients with recurrent mitral regurgitation (MR) has confronted surgeons with the issue of how to explant the devices and whether the mitral valve should be repaired or replaced. The aim of the study is to summarize our clinical experience with the explantation of different TMVr devices and to provide alternative surgical techniques that can be performed in different clinical scenarios.

**Methods:** A simulator system including a dummy valve representing native valves was used to create video documentation and to develop alternative surgical methods for clip explantation. Moreover, the clip explantation techniques were shown in 2 patients undergoing minimally-invasive mitral valve repair after a failed TMVr.

**Results:** Alternative explantation techniques were described for each TMVr device; 2 techniques for MitraClip and 3 techniques for PASCAL (Precision Transcatheter Valve Repair System), which may be adjusted for each individual according to the underlying valve pathology and the degree of device encapsulation. The patients were discharged without residual MR and remained MR free at the follow-up.

**Conclusions:** Transcatheter edge-to-edge repair devices can be surgically explanted without damaging the MV leaflets. Removal of each device may require a different technique tailored to the degree of device encapsulation and valve pathology. Increasing experience may facilitate repair in patients with recurrent MR after TMVr. (JTCVS Techniques 2023;21:65-71)



Video documentation regarding explantation techniques using the Fehling simulator.

## CENTRAL MESSAGE

Various surgical explantation techniques can be performed without damaging the MV leaflet in a minimally invasive setting. The removal of clip may make MV repair possible in patients with recurrent MR.

## PERSPECTIVE

Various surgical explantation techniques can be performed without damaging the MV leaflet in a minimally invasive setting.

See Discussion on page 72.

▶ Video clip is available online.

To view the AATS Annual Meeting Webcast, see the URL next to the webcast thumbnail.

From the <sup>a</sup>Department of Cardiothoracic and Vascular Surgery, Deutsches Herzzentrum der Charité (DHZC), Berlin, Germany; <sup>b</sup>Department of Cardiovascular Surgery, Charité-Universitätsmedizin Berlin, Berlin, Germany; <sup>c</sup>DZHK (German Center of Cardiovascular Research), Partner Site, Berlin, Germany; and <sup>d</sup>Department of Health Sciences and Technology, ETH Zurich, Zürich, Switzerland.

The PASCAL device was provided by Edwards to be simulated for possible explantation techniques in the Fehling simulator system. There is no funding.

Read at the 103rd Annual Meeting of The American Association for Thoracic Surgery, Los Angeles, California, May 6-9, 2023.

Received for publication April 4, 2023; revisions received May 4, 2023; accepted for publication May 22, 2023; available ahead of print July 6, 2023.

Address for reprints: Serdar Akansel, MD, Department of Cardiothoracic and Vascular Surgery, Deutsches Herzzentrum der Charité (DHZC), Augustenburger Platz 1, 13353, Berlin, Germany (E-mail: [serdar.akansel@dhzc-charite.de](mailto:serdar.akansel@dhzc-charite.de)). 2666-2507

Copyright © 2023 The Author(s). Published by Elsevier Inc. on behalf of The American Association for Thoracic Surgery. This is an open access article under the CC BY-NC-ND license (<http://creativecommons.org/licenses/by-nc-nd/4.0/>). <https://doi.org/10.1016/j.jtc.2023.05.023>

**Abbreviations and Acronyms**

AML	= anterior mitral leaflet
DMR	= degenerative mitral regurgitation
MI-MVr	= minimally invasive mitral valve repair
MR	= mitral regurgitation
MV	= mitral valve
PASCAL	= Precision Transcatheter Valve Repair System
PML	= posterior mitral leaflet
TEE	= transesophageal echocardiography
TMVr	= transcatheter mitral valve repair

The use of transcatheter mitral valve repair (TMVr) devices has become popular in elderly and high-risk patients over the last decade. However, it has been reported that 2.8% to 6.3% of these patients required mitral valve (MV) surgery due to recurrent mitral regurgitation (MR) at 1-year follow-up.<sup>1-4</sup> Therefore, the increasing number of the patients with recurrent MR has confronted surgeons with the issue of how to explant failed devices and whether MV should be repaired or replaced.<sup>5-9</sup> Experience regarding device explantation and MV repair management is still limited. The aim of the study is to summarize our clinical experience with explantation of the different TMVr devices such as MitraClip (Abbott) and PASCAL (Precision Transcatheter Valve Repair System; Edwards Lifesciences), and to provide alternative surgical techniques for different clinical scenarios.

**METHODS**

The Fehling simulator system, which includes a dummy valve representing the native valves, was used to create video documentation and to develop alternative surgical methods for clip explantation (Figure 1).<sup>10</sup> Moreover, the clip-explantation techniques were shown in 2 patients undergoing minimally invasive mitral valve repair (MI-MVr) after a failed TMVr. See Figure 2 for a graphical abstract of the study. The alternative surgical-explantation techniques tailored to the degree of device encapsulation and type of device are summarized in Table 1. The presented techniques are described on the basis of our 10-year experience with such operations and previously reported papers,<sup>11,12</sup> experience gained by practicing with the simulator system, and the manufacturer's recommendation.

In our center, a total of 69 patients underwent minimally invasive (n = 46) or full sternotomy (n = 23) MV surgery after failed TMVr. Five patients in the degenerative mitral regurgitation (DMR) group (n = 10) underwent MV repair. The operative management of the patients undergoing MV surgery after failed TMVr is summarized in Figure 3. The patients underwent a MI-MVr through a right anterolateral thoracotomy, with 3-dimensional fully endoscopic visualization as previously described in detail elsewhere.<sup>13</sup> Cardiopulmonary bypass was established by cannulation of the femoral artery and vein using a percutaneous technique. Myocardial protection was achieved by mild systemic hypothermia and antegrade infusion of cold del Nido cardioplegia following crossclamping.

The study was approved by the institutional ethics committee (Charité Ethics Committee, Berlin; approval number EA4/041/21, November 21, 2019). Written consent for publication of study data was obtained from all patients. Both patients were treated in accordance with the respective

European Society of Cardiology/European Association for Cardio-Thoracic Surgery guidelines.<sup>14</sup>

**Case 1: MI-MVr Following Failed MitraClip**

An 87-year-old female patient presented with recurrent severe MR 4 months after TMVr with 3 MitraClip implants due to DMR. She had progressive dyspnea and New York Heart Association functional class III cardiac decompensation signs on readmission. The European System for Cardiac Operative Risk Evaluation II and the Society of Thoracic Surgeons Predicted Risk of Mortality Score were 9.14 and 5.03, respectively. Preoperative transesophageal echocardiography (TEE) confirmed severe MR with an eccentric jet. Left ventricular ejection fraction was 55%, and effective regurgitant orifice area and left ventricular end-diastolic diameter were 0.49 cm<sup>2</sup> and 64 mm, respectively. The mean transmitral pressure gradient was 9.7 mm Hg.

**The Techniques Described Using the Fehling Simulator**

Two techniques for MitraClip removal were defined preoperatively using the Fehling simulator system. As the first technique, a suture was placed through the loops of the lock harness, which are located between the internal arms and act as a lock. As the suture was retracted, a forward pressure was applied by advancing a snare, a Frazier suction tube, or a Cor-Knot suture-fastening system (LSI Solutions) toward the lock (Figure 4, A). Alternatively, upward tension could be applied, by stabilizing the central part of the clip with forceps. By this maneuver, the locking mechanism was released, as shown in Video 1. By grasping the inner arms with a forceps, the clip was detached from the anterior mitral leaflet (AML) and posterior mitral leaflet (PML) subsequently.

The second technique included an approach with or without suturing through the loops; the internal arms were grasped using a forceps. The hooks of the internal arms were thus separated from the leaflets. Then, the device was pushed toward the apex and pulled back with another forceps to remove it from the leaflets.


**Surgical Treatment**

The MV repair included ring annuloplasty, triangular resection of the PML, and neochordae implantation on the AML and PML. The maze procedure using cryoablation and left atrial appendage closure was concomitantly performed.

Intraoperatively, the MV apparatus and implanted MitraClip devices were evaluated. The first clip was removed with an explantation technique including placing a suture through the loops of the lock harness. As the suture was retracted, a forward pressure was applied by advancing the snare toward the lock (Figure 4, B). Upward tension could also be applied, as stabilizing the central part of the clip with forceps. By this maneuver, the locking mechanism was released, as shown in Video 1. By grasping the inner arms with a forceps, the clip was detached from the AML and PML subsequently.

In some cases, the clips can become highly encapsulated by fibrin tissue over time. In this case, the second technique can be performed. The clip is dissected from the fibrin tissue to reach to loops of the lock harness as previously described.<sup>11</sup>

As shown in the first technique, a suture was placed through the loops and then the internal arms were grasped using a forceps. The hooks of the internal arms were thus separated from the leaflet. Then, the device was pushed toward the apex and pulled back with another forceps. Subsequently, the MV was evaluated for eligibility of repair. The excess tissue on the PML was then resected by a triangular resection technique. The PML was repaired with a 6/0 Cardioynl suture (Peters Surgical Inc, Paris, France). Thereafter, the length of the neochordae was measured. Two neochordae were implanted on the AML and PML. After the measurement for the optimal ring sizing, a 34-mm Carpentier-Edwards Physio II



**FIGURE 1.** Video documentation regarding explantation techniques using Fehling simulator system including a dummy valve representing native MV. MV, Mitral valve.

Ring (Edwards Lifesciences) was implanted. The water test showed a good leaflet coaptation without leakage.

The postrepair TEE confirmed a good coaptation depth without residual MR. The coaptation depth was 11 mm. The mean transmitral pressure gradient decreased approximately 4.1 mm Hg. At the 1-year follow-up, the patient remained MR free.

## Case 2: MI-MVr Following Failed PASCAL Implantation

The second patient with recurrent severe DMR was a 70-year-old male patient who was referred to our clinic with New York Heart Association class III cardiac decompensation signs 1 month after failed TMVr with 2 PASCAL implants. European System for Cardiac Operative Risk Evaluation II and Society of Thoracic Surgeons Predicted Risk of Mortality Score were 4.74% and 3.36%, respectively. Preoperative TEE confirmed severe MR and device malposition. Left ventricular ejection fraction was 60%, and effective regurgitant orifice area and left ventricular end-diastolic diameter were 0.55 cm<sup>2</sup> and 63 mm, respectively.

### The Techniques Described Using Fehling Simulator

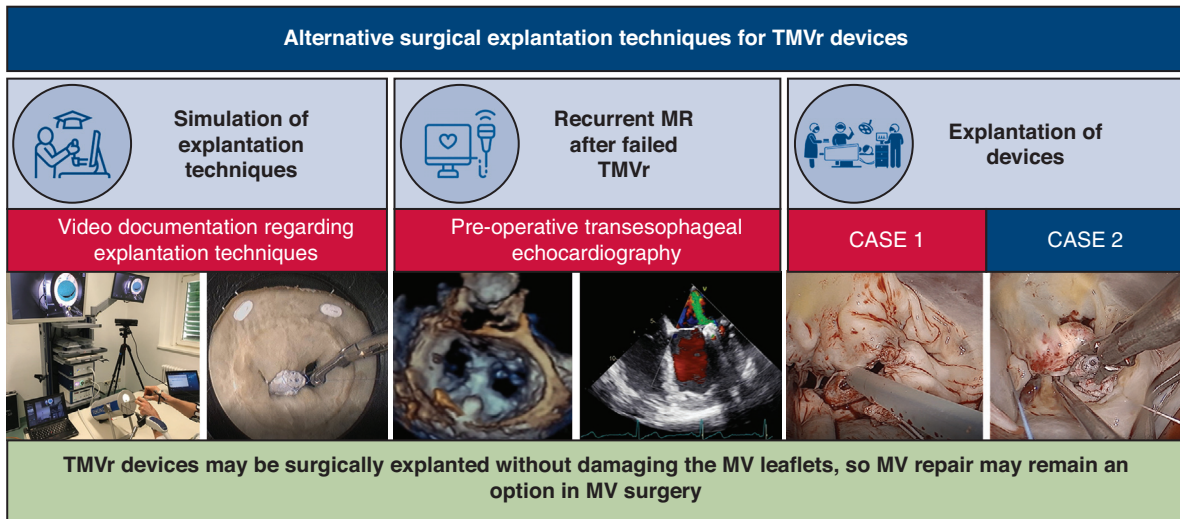
In the Fehling simulator system, different techniques regarding explantation of the PASCAL device explored by Edwards were simulated as follows. The first technique<sup>12</sup> is called the “suture-securing technique”; the inner arms of the device were attached to the central spacer with a PROLENE suture (Figure 5, A). While the central spacer was held in place by a forceps, the leaflet was gently pushed out from the central spacer. After the leaflet has been released from internal paddle, the partially opened device should be gently pushed towards the apex. The maneuver should also be repeated for the PML.

The second technique is the “walking-down method”; the internal arms were grasped using a forceps. The hooks of the internal arms were thus separated from the leaflets. The leaflet was held and gently pushed away from the central spacer. After the leaflet has been released from the internal paddle, the partially opened device should be gently pushed towards the apex. The maneuver should also be repeated for the PML.

The third technique is called “Elevator method”; first, the central spacer was grasped using a forceps. The anterior clasp was then gently pushed away from the central spacer. The forceps grasping the internal arm was gently introduced deeper. The device was then pushed toward the apex and released from the AML. The maneuver should also be repeated for the PML. Additionally, since the PASCAL device has a nitinol-based soft-locking system, the removal techniques can be combined with the use of a cold saline solution.

### Surgical Treatment

The second patient underwent a MI-MVr including ring annuloplasty, resection of the calcified cyst at P2 and implantation of neochordae on the AML and PML, and concomitantly the maze procedure using cryoablation. MV apparatus and the implanted PASCAL devices were evaluated intraoperatively, as shown in Video 1. First, the PML edge grasped by the device arms was cut and released from the PML. Then, the central spacer was grasped with a forceps and retracted subsequently (Figure 5, B). The device was released from the AML with this maneuver. Thereafter, the second PASCAL device was found free in the LV cavity. Subsequently, the MV was evaluated for repair eligibility. Two neochordae loops were implanted on the AML and PML. After the measurement for the optimal ring sizing, a 36-mm Physio II ring was implanted. A calcified cyst found at P2 was removed by sharp dissection. The PML was repaired with a 6/0 Cardioynl suture. The water test showed a good coaptation of the leaflets without leakage.



TMVr: Transcatheter mitral valve repair  
MR: Mitral regurgitation; MV: Mitral valve

Akansel, S et al, 2023 DEUTSCHES HERZZENTRUM DER CHARITE

**FIGURE 2.** Alternative surgical explantation techniques for failed TMVr devices such as MitraClip and PASCAL; illustration of simulator system, preoperative TEE images, operative illustration regarding explantation of failed devices (from left to right). *TMVr*, Transcatheter mitral valve repair; *MR*, mitral regurgitation; *MV*, mitral valve.

The postrepair TEE confirmed a good coaptation depth without residual MR. The coaptation depth was 9.6 mm. The mean transmitral pressure gradient decreased around 1.9 mm Hg. At the 2-year follow-up, the patient remained MR free.

**DISCUSSION**

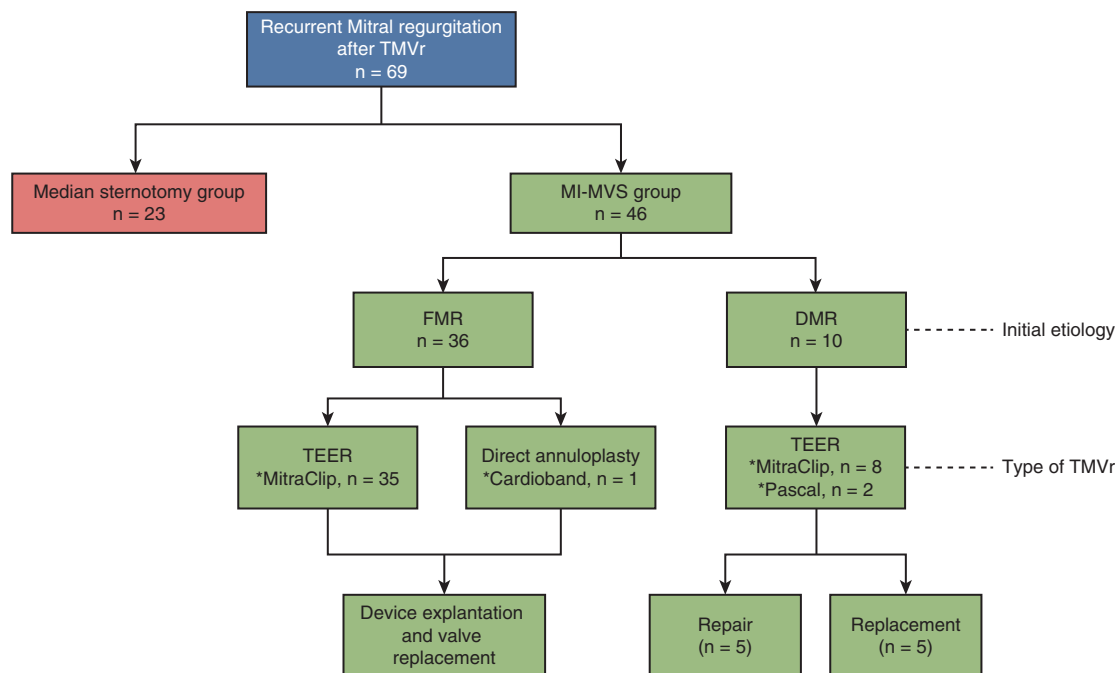
This study investigated alternative surgical techniques for the explantation of failed TMVr devices to provide a removal guidance in different clinical scenarios. The main messages and findings from the present study can be summarized as follows: (1) Transcatheter edge-to-edge repair devices can be surgically explanted without damaging the MV leaflets. (2) Each device may require a

different technique for the removal. (3) In the case of a highly encapsulated device, it may be necessary to dissect the device from the surrounding tissue and then perform an appropriate explantation technique.

As the clinical use of TMVr devices increases, the question of how to overcome recurrent MR after failed devices is being raised.<sup>6</sup> The surgical reoperation may be more challenging than usual in high-risk patients who were not previously deemed as appropriate candidates for open-heart surgery or in patients with clip-induced complex mitral anatomy in whom valve repair could be previously considered.<sup>5,7</sup> It remains unclear how the device should be explanted and whether MV should be repaired or

**TABLE 1.** The alternative explantation techniques tailored to the degree of device encapsulation, type of device

Clinical scenario	Techniques
MitraClip	
Newly implanted	First technique; placing a suture through the loops, unlocking the mechanism
Implanted long ago	Second technique; dissection of fibrin tissue, grasping internal arms and separating hooks from the leaflet
PASCAL	
Newly implanted	Suture securing technique; suturing internal paddles to central spacer, pushing external paddles away from the central spacer Elevator technique; grasping internal arm and introducing deeper to separated hooks from the leaflet
Implanted long ago	Walking-down method; dissection of fibrin tissue between the arms, grasping central spacer, pushing internal arm away from the central spacer, detachment of internal arm from the leaflet

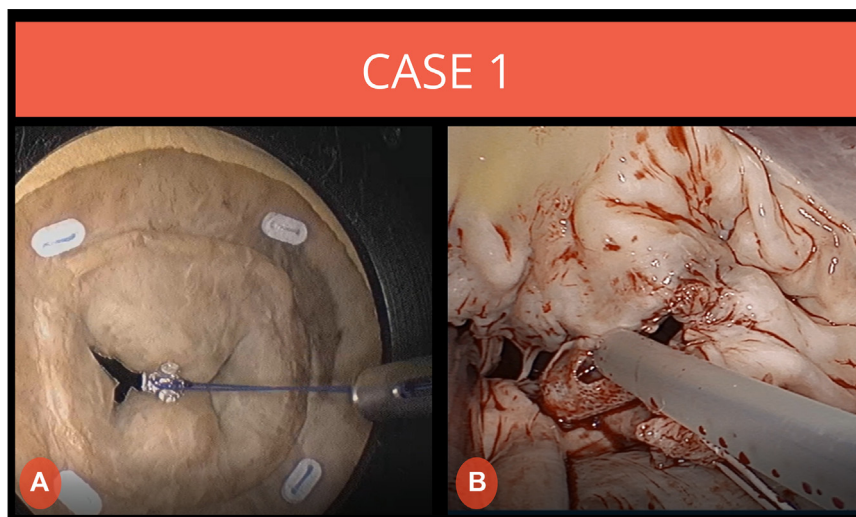


**FIGURE 3.** Flowchart showing patient population undergoing mitral valve surgery after failed TMVr. *TMVr*, Transcatheter mitral valve repair; *MI-MVS*, minimally invasive mitral valve surgery; *FMR*, functional mitral regurgitation; *DMR*, degenerative mitral regurgitation; *TEER*, transcatheter edge-to-edge repair.


replaced. The feasibility of surgical MV repair after TMVr has been evaluated in several studies.<sup>5-9</sup> In addition, several cases of device explantation after failed TMVr have been reported.<sup>11,12</sup> Gerçek and colleagues<sup>12</sup> have reported the first case on the surgical removal of the PASCAL device and demonstrated that surgical removal of the PASCAL device without leaflet injury is possible. However, the type of

device and degree of device encapsulation may potentially complicate injury-free device removal. Therefore, removal of each device may require a different technique tailored to the degree of device encapsulation, type of device, and underlying valve pathology.

Although clip-induced leaflet or chordal damage may make valve repair unfeasible in some cases, the fact that



**FIGURE 4.** Illustration of the explantation technique using the simulator system; suturing through the loops of the lock harness located between the internal arms (A). Unlocking maneuver by applying forward pressure with advancing the snare toward the lock while retracting the suture (B).



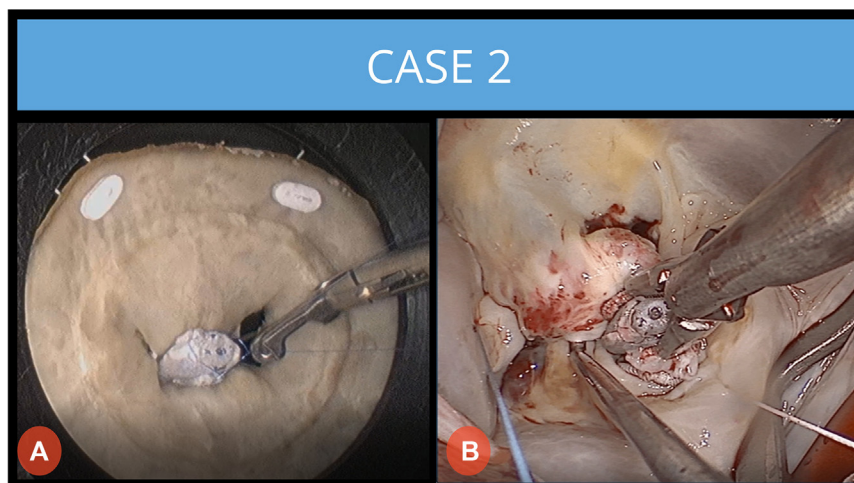
**VIDEO 1.** Documentation of alternative surgical techniques for failed TMVr devices using Fehling simulator system and performing these techniques in 2 patients undergoing MI-MVr after failed TMVr. Video available at: [https://www.jtcvs.org/article/S2666-2507\(23\)00202-X/fulltext](https://www.jtcvs.org/article/S2666-2507(23)00202-X/fulltext).

the patient has previously undergone TMVr alone does not mean that the MV should be considered unreparable.<sup>7</sup> Our decision-making strategy was based on underlying valve pathology, the type of device, and the leaflet integrity. Due to the risk of recurrent MR following MV repair, patients with FMR should undergo MV replacement. In patients with DMR etiology, the surgical approach was based on the following criteria: (1) If there was no loss-of-leaflet insertion, the clip was kept in place and ring annuloplasty was performed to support the annulus. Additional leaflet repair techniques may be performed as needed. Loss-of-leaflet insertion was considered as a criterion for clip removal. The integrity of the AML and the feasibility of PML repair were decisive for the subsequent strategy. MV replacement should be considered if the AML is damaged and the PML is found to be unreparable.<sup>7</sup> Furthermore, in patients who underwent TMVr long ago, the encapsulation of the clip may limit a

damage-free explantation, making a durable repair unlikely. Our treatment of choice in such patients is MV replacement. In the present paper, we demonstrated several removal methods that can be performed without leaflet damaging in different scenarios. The aforementioned techniques were described both in vitro on dummy valves using the Fehling simulator system and in patients with recurrent MR after failed TMVr in whom valve repair could be successfully performed. The Fehling simulator was used to establish the removal concepts presented in this study and may act as training tool before clinical cases. Based on the findings and the clear description of how clips can be removed, we estimate only a few training cases to complete the learning curve with the Fehling Simulator beforehand are required be proficient enough for clinical cases. These overall concept of in vitro training and deep knowledge regarding clip removal techniques may make repair possible in patients with favorable MV anatomy and pathology.

The presented manuscript is somehow limited by the fact that only patients referred to our hospital can be included in the study. Patients who received their clip implantation at an external hospital who were treated conservatively despite clip-failure with severe MR are not reflected in our study. This fact should be considered when interpreting the overall numbers of failed clips treated surgically. However, the primary scope of this article is to describe techniques of clip removal.

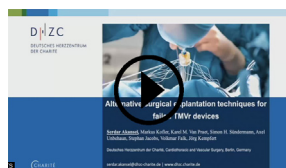
As a conclusion, transcatheter edge-to-edge repair devices may be surgically explanted without damaging the MV leaflets. Each device may require a different technique for removal. MV repair may remain an option in MV surgery for patients with recurrent MR after failed TMVr. Increasing experience may facilitate MV repair in patients with recurrent MR after TMVr.



**FIGURE 5.** Illustration of explantation technique using the simulator system; suturing internal paddles to central spacer (A); release of the device from the AML and PML by grasping the central spacer and pulling it back with forceps (B).

## Webcast

You can watch a Webcast of this AATS meeting presentation by going to: <https://www.aats.org/resources/alternative-surgical-explantation-techniques-of-transcatheter-mitral-valve-repair-devices>.



## Conflict of Interest Statement

The authors reported no conflicts of interest.

The *Journal* policy requires editors and reviewers to disclose conflicts of interest and to decline handling or reviewing manuscripts for which they may have a conflict of interest. The editors and reviewers of this article have no conflicts of interest.

## References

- Puls M, Lubos E, Boekstegers P, von Bardeleben RS, Ouarrak T, Butter C, et al. One-year outcomes and predictors of mortality after MitraClip therapy in contemporary clinical practice: results from the German transcatheter mitral valve interventions registry. *Eur Heart J*. 2016;37:703-12.
- Sorajja P, Vemulapalli S, Feldman T, Mack M, Holmes DR, Stebbins A, et al. Outcomes with transcatheter mitral valve repair in the United States: an STS/ACC TVT registry report. *J Am Coll Cardiol*. 2017;70:2315-27.
- Feldman T, Kar S, Elmariah S, Smart SC, Trento A, Siegel RJ, et al; EVEREST II Investigators. Randomized comparison of percutaneous repair and surgery for mitral regurgitation: 5-year results of EVEREST II. *J Am Coll Cardiol*. 2015; 66:2844-54.
- Maisano F, Franzen O, Baldus S, Schäfer U, Hausleiter J, Butter C, et al. Percutaneous mitral valve interventions in the real world: early and 1-year results from the ACCESS-EU, a prospective, multicenter, nonrandomized post-approval study of the MitraClip therapy in Europe. *J Am Coll Cardiol*. 2013;62:1052-61.
- Argenziano M, Skipper E, Heimansohn D, Letsou GV, Woo YJ, Kron I, et al; EVEREST Investigators. Surgical revision after percutaneous mitral repair with the MitraClip device. *Ann Thorac Surg*. 2010;89:72-80.
- Geidel S, Schmoekel M. Impact of failed mitral clipping on subsequent mitral valve operations. *Ann Thorac Surg*. 2014;97:56-63.
- Akansel S, Kofler M, Van Praet KM, Unbehaun A, Sündermann SH, Jacobs S, et al. Minimally invasive mitral valve surgery after failed transcatheter mitral valve repair in an intermediate-risk cohort. *Interact Cardiovasc Thorac Surg*. 2022;35:ivac163.
- Takayuki G, Sören S, Kristin R, Harnath A, Grimmig O, Sören J, et al. Surgical revision of failed percutaneous edge-to-edge mitral valve repair: lessons learned. *Interact Cardiovasc Thorac Surg*. 2019;28:900-7.
- Kaneko T, Hirji S, Zaid S, Lange R, Kempfert J, Conradi L, et al. Mitral valve surgery after transcatheter edge-to-edge repair: mid-term outcomes from the CUTTING-EDGE International Registry. *JACC Cardiovasc Interv*. 2021;14: 2010-21.
- Jebran AF, Saha S, Waezi N, Al-Ahmad A, Niehaus H, Danner BC, et al. Design and training effects of a physical reality simulator for minimally invasive mitral valve surgery. *Interact Cardiovasc Thorac Surg*. 2019; 29:409-15.
- Akansel S, Sündermann SM, Kofler M, Van Praet KM, Kukucka M, Falk V, et al. A successful minimally invasive mitral valve repair following delayed device embolization in a patient with PASCAL device implantation. *Türk Gogus Kalp Damar Cerrahisi Derg*. 2020;28:404-6.
- Geçek M, Hakim-Meibodi K, Rudolph V, Gummert J, Deutsch MA. First report on the surgical removal of the PASCAL device after failed transcatheter mitral valve repair. *JACC Cardiovasc Interv*. 2020;13:651-2.
- Van Praet KM, Kempfert J, Jacobs S, Stamm C, Akansel S, Kofler M, et al. Mitral valve surgery: current status and future prospects of the minimally invasive approach. *Expert Rev Med Devices*. 2021;18:245-60.
- Vahanian A, Beyersdorf F, Praz F, Milojevic M, Baldus S, Bauersachs J, et al ESC/EACTS Scientific document group, ESC National Cardiac Societies. 2021 ESC/EACTS guidelines for the management of valvular heart disease: developed by the task force for the management of valvular heart disease of the European Society of Cardiology (ESC) and the European Association for Cardio-Thoracic surgery (EACTS). *Eur Heart J*. 2022;43:561-632.

**Key Words:** transcatheter mitral valve repair, failed TMVr, TEER, device explantation, MitraClip, PASCAL